EUROPEAN UROLOGY 66 (2014) 542–549

available at www.sciencedirect.com
journal homepage: www.europeanurology.com

European Association of Urology

Surgery in Motion

Technique and Outcomes of Robot-assisted Retroperitoneoscopic Partial Nephrectomy: A Multicenter Study

Jim C. Hu [a,*,†], *Eric Treat* [a,†], *Christopher P. Filson* [a], *Ian McLaren* [b], *Siwei Xiong* [a], *Sevan Stepanian* [c], *Khaled S. Hafez* [b], *Alon Z. Weizer* [b,‡], *James Porter* [c,‡]

[a] *Department of Urology, David Geffen School of Medicine at UCLA, Los Angeles, CA, USA;* [b] *Department of Urology, University of Michigan, Ann Arbor, MI, USA;* [c] *Swedish Medical Center, Seattle, WA, USA*

Article info

Article history:
Accepted April 26, 2014

Keywords:
Renal cell carcinoma
Partial nephrectomy
Robotic surgery
Retroperitoneal approach
Outcomes

Please visit www.europeanurology.com and www.urosource.com to view the accompanying video.

Abstract

Background: Robot-assisted retroperitoneoscopic partial nephrectomy (RARPN) may be used for posterior renal masses or with prior abdominal surgery; however, there is relatively less familiarity with RARPN.
Objective: To demonstrate RARPN technique and outcomes.
Design, setting, and participants: A retrospective multicenter study of 227 consecutive RARPNs was performed at the Swedish Medical Center, the University of Michigan, and the University of California, Los Angeles, from 2006 to 2013.
Surgical procedure: RARPN.
Outcome measurements and statistical analysis: We assessed positive margins and cancer recurrence. Stepwise regression was used to examine factors associated with complications, estimated blood loss (EBL), warm ischemia time (WIT), operative time (OT), and length of stay (LOS).
Results and limitations: The median age was 60 yr (interquartile range [IQR]: 52–66), and the median body mass index (BMI) was 28.2 kg/m^2 (IQR: 25.6–32.6). Median maximum tumor diameter was 2.3 cm (IQR: 1.7–3.1). Median OT and WIT were 165 min (IQR: 134–200) and 19 min (IQR: 16–24), respectively; median EBL was 75 ml (IQR: 50–150), and median LOS was 2 d (IQR: 1–3). Twenty-eight subjects (12.3%) experienced complications, three (1.3%) had urine leaks, and three (1.3%) had pseudoaneurysms that required reintervention. There was one conversion to radical nephrectomy and three transfusions. Overall, 143 clear cell carcinomas (62.6%) composed most of the histology with eight positive margins (3.5%) and two recurrences (0.9%) with a median follow-up of 2.7 yr. In adjusted analyses, intersurgeon variation was associated with complications (odds ratio [OR]: 3.66; 95% confidence interval, 1.31–10.27; $p = 0.014$) and WIT (parameter estimate [PE; plus or minus standard error]: 4.84 ± 2.14; $p = 0.025$). Higher surgeon volume was associated with shorter WIT (PE: -0.06 ± 0.02; $p = 0.002$). Higher BMI was associated with longer OT (PE: 2.09 ± 0.56; $p < 0.001$). Longer OT was associated with longer LOS (PE: 0.01 ± 0.01; $p = 0.002$). Finally, there was a trend for intersurgeon variation in OT (PE: 18.5 ± 10.3; $p = 0.075$).
Conclusions: RARPN has acceptable morbidity and oncologic outcomes, despite intersurgeon variation in WIT and complications. Greater experience is associated with shorter WIT.
Patient summary: Robot-assisted retroperitoneoscopic partial nephrectomy has acceptable morbidity and oncologic outcomes, and there is intersurgeon variation in warm ischemia time and complications.

† Contributed equally as first author.
‡ Contributed equally as last author.
* Corresponding author. Department of Urology, 924 Westwood Blvd., Ste. 1000, Los Angeles, CA 90024, USA. Tel. +1 310 825 1172.
E-mail address: jchu@mednet.ucla.edu (J.C. Hu).

http://dx.doi.org/10.1016/j.eururo.2014.04.028
0302-2838/

1. Introduction

The incidence of small renal masses has been increasing, and partial nephrectomy has become the gold standard for the treatment of T1a (<4 cm) renal tumors in the setting of a normal contralateral kidney [1]. Although there is greater acknowledgment that nephron-sparing approaches are underused [2], most partial nephrectomies are performed through an open approach despite the lower morbidity and shorter hospitalization of minimally invasive surgery. For instance, the open, robotic, and laparoscopic approaches accounted for 79%, 11.5%, and 9.5%, respectively, of all partial nephrectomies performed in the United States in 2008 [3].

Tumor location factors into treatment decision making. Some centers prefer percutaneous thermal ablation for posterior and lateral tumors [4]; others prefer a retroperitoneoscopic partial nephrectomy approach [5]. Although the retroperitoneoscopic approach was first described by Gaur et al. in 1993 [6], there has been relatively less adoption and utilization compared with transperitoneal laparoscopic approaches. This may be due to larger working space and more anatomic landmarks afforded by the transperitoneal laparoscopic approach. However, transperitoneal access to posterior renal tumors requires bowel mobilization and full kidney mobilization to flip the kidney medially, which may challenge the field of view due to the proximity of the renal mass to the laparoscope. Conversely, the retroperitoneal approach is limited by a smaller working space, and the absence of anatomic landmarks may disorient and risk inadvertent vascular injury requiring open conversion [7]. However, this approach also minimizes the risk of bowel injury, particularly with prior abdominal surgery.

Given the challenging learning curve of minimally invasive and robotic surgery and less use of retroperitoneoscopic minimally invasive surgery, the objective of our study was to illustrate our surgical approach and outcomes with robot-assisted retroperitoneoscopic partial nephrectomy (RARPN) to facilitate its adoption.

2. Methods and patients

Our study was approved by the institutional review boards of the Swedish Medical Center (SMC); the University of California, Los Angeles (UCLA); and the University of Michigan (UM), and data were prospectively collected for 227 consecutive robot-assisted retroperitoneoscopic partial nephrectomies performed by J.P., J.C.H., and A.Z.W. from June 2006 to November 2013. All surgeons had performed conventional retroperitoneoscopy and >40 robot-assisted transperitoneal partial nephrectomies prior to initiating RARPN. Our initial approach to RARPN has been described [8,9], and we describe modifications and institutional variation with trocar placement and renorrhaphy. All attempted RARPNs were included without exclusion.

2.1. Surgical technique

2.1.1. Patient preparation

For retroperitoneal approaches, we do not administer bowel preps, and patients are limited to a clear liquid diet the day before surgery. A type and screen is sent before incision.

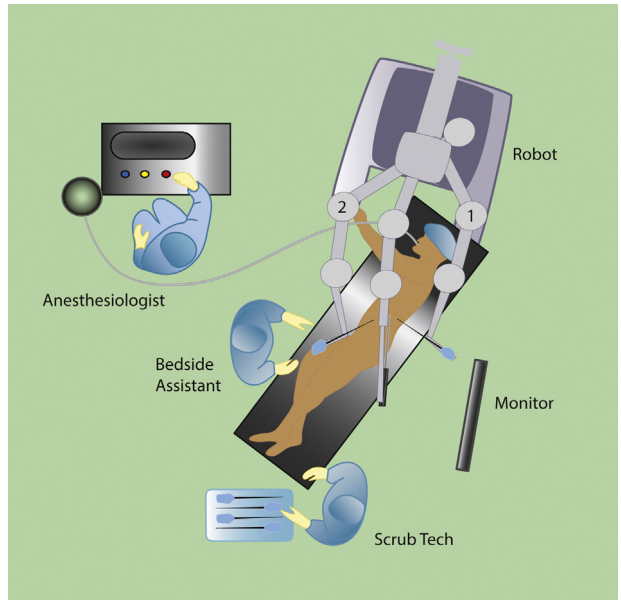

Fig. 1 – A long circuit may be needed by anesthesia to accommodate docking of the robot over the patient's head for robot-assisted retroperitoneoscopic partial nephrectomy.

2.1.2. Patient positioning

After intubation and bladder catheterization, patients are placed in full flank (decubitus position) with the ipsilateral side up relative to the renal tumor. In addition, an axillary roll is placed and the ipsilateral arm is secured with an airplane. The dependent arm is padded and secured close to the face to avoid blocking the robot from being docked in the best position. The bed is fully flexed to provide maximal space between the ribs and the iliac crest. The patient is secured with 4-inch cloth tape across the chest and pelvis. In addition, a long circuit is attached from the endotracheal tube to the ventilator to ensure adequate working space for the anesthesiologist in anticipation of the robot docking parallel and very close to the ipsilateral arm (Fig. 1).

2.1.3. Creation of retroperitoneal space and trocar placement

SMC and UCLA share the same trocar placement, whereas UM places the robotic trocars more cephalad; however, all institutions use the AirSeal System (SurgiQuest, Inc., Milford, CT, USA), which mitigates against inadvertent loss of pneumoretroperitoneum. All study surgeons did not use a fourth robotic arm due to the smaller working space and trocar distances of retroperitoneoscopy. At SMC and UCLA, a skin incision is made 1–2 cm above the iliac crest in the midaxillary line (Fig. 2A). At UCLA, a 12-mm trocar with a visual obturator and a zero-degree 10-mm laparoscope is used to tunnel through the subcutaneous adipose tissue, flank musculature, and the lumbodorsal fascia to the retroperitoneal fat. Alternatively, at SMC, blunt dissection is used to pop through the lumbodorsal fascial, and finger dissection is used to initialize creation of the retroperitoneal space. Next, the laparoscopic hernia balloon (Covidien OMSPDBS2, Mansfield, MA, USA) is inflated under direct laparoscopic vision. Care is taken to ensure that the kidney-shaped hernia balloon expands with its wings in a cranial-caudad direction posterior to the kidney. The ureter and gonadal vein are usually visualized with expansion of the balloon ventral to the psoas muscle. After full expansion, the hernia balloon is removed, and the 12-mm trocar is reinserted for insufflation of the retroperitoneum with 15 mm Hg of carbon dioxide (CO_2). The 8-mm robotic trocar is placed in the posterior axillary line in a horizontal plane approximately 2 cm cephalad to the 12-mm camera port. A laparoscopic Kittner is used to reflect the peritoneum medially and downward to allow

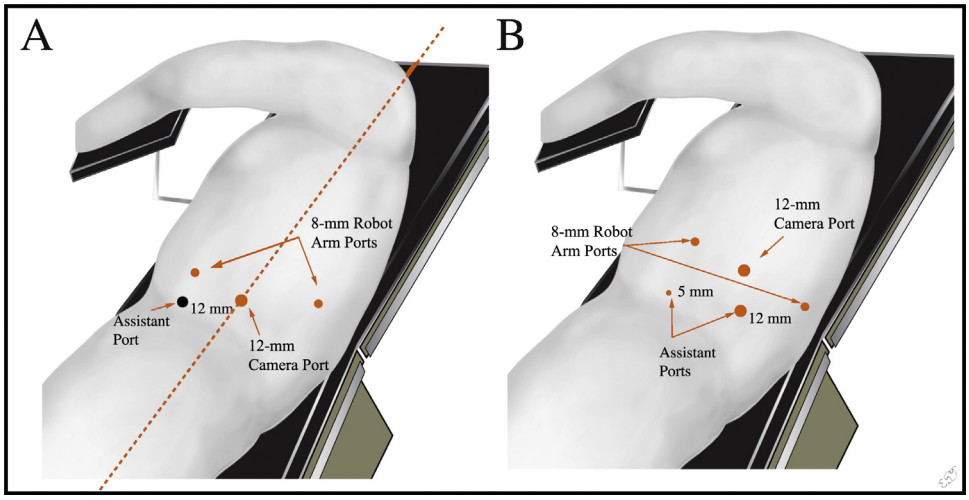

Fig. 2 – Trocar configuration: (A) University of California, Los Angeles, and the Swedish Medical Center; (B) University of Michigan.

insertion of a second 8-mm robotic trocar in the anterior axillary line in a horizontal plane approximately 1 cm caudad to the first robotic trocar. Finally, after ensuring the peritoneum is reflected 2 cm medial to the anterior superior iliac spine, a 12-mm assistant trocar is inserted at this location. The robot is docked (Fig. 1) over the forehead of the patient, and the robotic scope is inserted in the 12-mm initial access trocar while the hot scissors and fenestrated bipolar forceps are inserted into the posterior and anterior robotic trocars, respectively. A zero-degree robotic scope is used throughout the case.

At UM, a 2-cm skin incision is made below the tip of the 12th rib and a Schnidt Tonsil clamp is used to enter the thoracolumbar fascia and the retroperitoneal space, followed by blunt finger dissection behind the kidney (Fig. 2B). The hernia balloon is placed posterior to the kidney aimed toward the ipsilateral shoulder to expand the space. A conventional 12-mm trocar is then placed and the space is insufflated. Leak is prevented by filling the incision with petroleum gauze secured in place by a purse-string suture of the skin. The first robotic trocar is placed at the costovertebral angle, and a laparoscopic Kittner is used to mobilize the peritoneum medially to place the second robotic trocar 2 cm below the 11th rib. Assistant surgeon 12- and 5-mm trocars are placed on either side of the anterior superior iliac spine with a tendency to place the ports as medial as possible to allow the assistant to lift the kidney if needed in cases of peritoneal leak. In addition, the 30°-up robotic lens is used, which allows the assistant surgeon more space at the bedside.

2.1.4. *Renal artery dissection*

The robotic scope is rotated so the psoas courses horizontally, and Gerota fascia is incised horizontally approximately 1 cm above the psoas (Fig. 3). The fenestrated bipolar forceps is used to lift the kidney upward, putting the hilum on stretch to facilitate dissection through the perinephric fat onto the pulsations of the renal artery. The artery is skeletonized to allow subsequent selective versus nonselective renal artery clamping (Fig. 4), based on patient anatomy, with the laparoscopic bulldog clamp. This dissection is often performed with only the robotic scissors, and hooking perihilar connective tissue and applying monopolar current facilitates this one-handed approach. Alternatively, the bedside assistant may lift the kidney with the laparoscopic suction or a blunt instrument to free the fenestrated bipolar forceps, particularly with the UM two-assistant trocar approach. The renal artery is landmarked as the midpole reference point relative to the location of the renal mass on cross-sectional imaging. The renal vein is not routinely dissected out and clamped, with the exception of very central renal tumors encroaching on the venous vasculature.

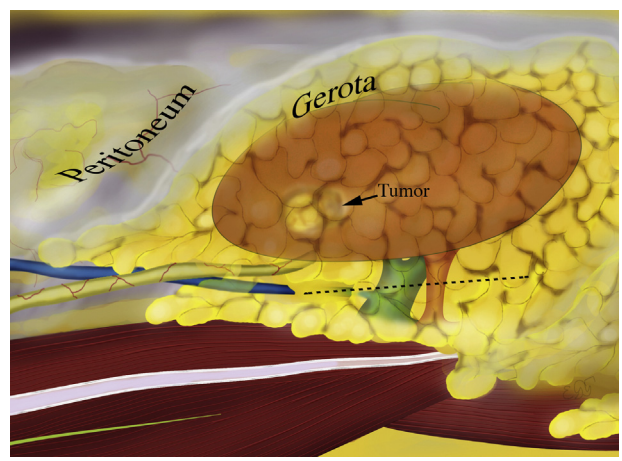

Fig. 3 – Retroperitoneal anatomic relationships. The robotic scope is turned so the psoas muscle is horizontal for orientation. In thinner patients, peristalsis of the ureter may be seen during and after balloon dissection of the retroperitoneum. Gerota fascia is incised horizontally above the psoas muscle.

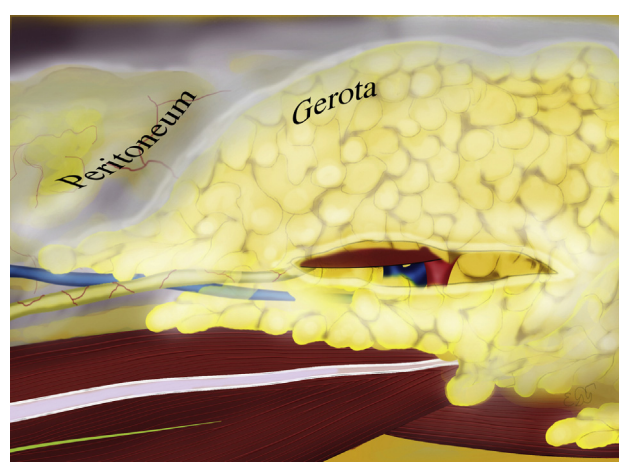

Fig. 4 – Arterial pulsations are helpful to identify the renal artery, which is skeletonized in anticipation of hilar vascular control.

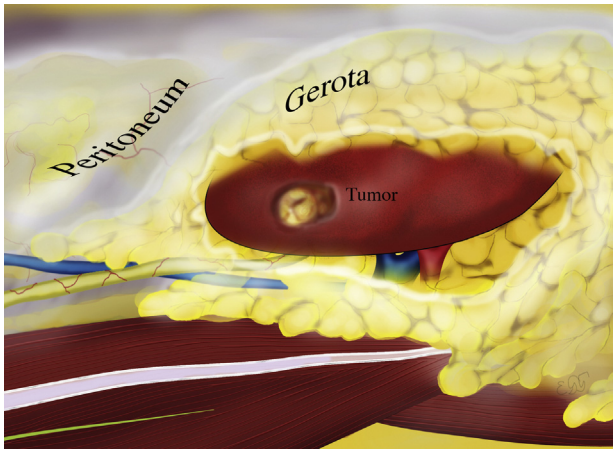

Fig. 5 – The hilum serves as a landmark relative to the tumor location, and the upper cut edge of Gerota fascia is used as a landmark to avoid inadvertent peritoneotomy. The kidney is defatted to identify the tumor.

Defatting of the kidney begins under the upper Gerota fascia cut edge, which is used as a landmark to avoid inadvertent peritoneotomy (Fig. 5). If there is CO_2 entry into the peritoneal space secondary to peritoneotomy and loss of the retroperitoneal space and exposure, a 5-mm trocar with a visual obturator may be inserted under direct laparoscopic vision to vent the peritoneal cavity; however, this was rarely required (two instances).

If we encounter difficulty with identifying the mass, we defat the kidney to identify its convex polar contour. Of note, tumors at the caudad extent of the kidney may be unreachable with the UM trocar placement and may require the transperitoneal approach.

Next, the laparoscopic ultrasound is used to identify and confirm tumor location, and cautery is used to circumscribe the planned renal capsule incision. Mannitol is administered (before indocyanine green in cases of selective renal artery clamping) prior to renal artery clamping. We go through a checklist to ensure there is adequate remaining use of the robotic needle drivers, the trocars have not backed out of their desired depth, and renorrhaphy sutures have been cut to the desired length and prepared to obviate the need for intracorporeal knot tying to minimize warm ischemia time (WIT). After clamping the main renal artery or a renal artery branch, cold scissor dissection is used to excise the tumor.

At UCLA, the first layer of the renorrhaphy is closed with a 3-0 barbed V-Loc suture (Covidien, Mansfield, MA, USA) in a running fashion, closing any collecting system injury and vascular structures. After placing the first bite of the second layer of the renorrhaphy with 2-0 absorbable polyfilament, the renal artery is unclamped and the horizontal mattress running suture is completed using the sliding clip technique [10]. At UM and SMC, a 4-0 absorbable monofilament is used to repair collecting system entry, and a 2-0 absorbable polyfilament is used to close sinus fat. A nitrocellulose bolster with two preplaced 0-absorbable polyfilament sutures is then secured with additional 0-absorbable polyfilament sutures to provide adequate compression, using the sliding clip technique, and hemostatic agents are used, if needed. The insufflation pressure is lowered to 5 mm Hg to ensure hemostasis prior to specimen and trocar removal and closure.

A 15F round drain is placed with collecting system entry through the more anterior 8-mm robotic trocar, after the specimen is placed into a laparoscopic bag and removed by enlarging the camera trocar incision. During wound closure, ketorolac is administered intravenously at UCLA, but not at UM or SMC.

2.2. *Statistical analyses*

Descriptive statistics were used to summarize our multicenter series. Stepwise logistic and linear regression was performed to adjust for independent variables such as age, body mass index (BMI), American Society of Anesthesiologists score, vascular variation (more than one renal artery or vein) nephrometry score, and surgeon volume (individual surgeon RARPN series ordinal case number). All tests were considered statistically significant at $\alpha = 0.05$. Statistical analyses were performed with SAS v.9.1.3 (SAS Institute, Cary, NC, USA).

3. Results

The median age was 60 yr (interquartile range [IQR]: 52–66), and the median BMI was 28.2 kg/m^2 (IQR: 25.6–32.6). Men composed 62.6% of the study sample, and a left renal mass was present in 119 (52.4%); 160 (70.5%) had a posterior location (Table 1). Twenty-nine of the subjects (12.8%) had a history of prior abdominal surgery. Most subjects had one renal artery (87.4%) and one renal vein (95.2%), respectively. Median maximum tumor diameter was 2.3 cm (IQR: 1.7–3.1), and most of the subjects (52.0%) had a nephrometry score between 5 and 8.

Median operative time (OT) and WIT were 165 min (IQR: 134–200) and 19 min (IQR: 16–24), respectively, and median length of stay (LOS) was 2 d (IQR: 1–3). The median intraoperative estimated blood loss (EBL) was 75 ml (IQR: 50–150), and three subjects required a transfusion (Table 2). Two subjects were transfused intraoperatively due to a high blood loss of 1600 ml and 2500 ml, respectively, and one of these subjects required conversion to radical nephrectomy due to refractory bleeding. Twenty-eight subjects (12.3%) experienced a complication. Six subjects required procedural intervention to correct Clavien grade 3 complications: three ureteral stent placements resolved urine leaks, and three pseudoaneurysms required angioembolization. Clear cell renal cell carcinoma (RCC) was identified in 143 subjects (62.6%), and there were eight (3.5%) positive surgical margins. Benign lesions were found in 45 subjects (19.8%). With a median follow-up of 2.7 mo, one subject with a positive surgical margin experienced a local recurrence; another subject with pT3a, negative margin, clear cell Fuhrman grade 4 developed metastases.

In adjusted analysis, there was significant intersurgeon heterogeneity for complications (odds ratio [OR]: 3.66; 95% confidence interval [CI], 1.31–10.27; $p = 0.014$) and WIT (parameter estimate [PE; plus or minus standard error]: 4.84 ± 2.14; $p = 0.025$). Higher surgeon volume was associated with shorter WIT (PE: -0.06 ± 0.02; $p = 0.002$). Higher BMI was associated with longer OTs (PE: 2.09 ± 0.49; $p < 0.001$); longer OTs were associated with longer LOS (PE: 0.01 ± 0.01; $p = 0.002$). Intersurgeon variation was associated with complications (OR: 3.66; 95% CI, 1.31–10.27; $p = 0.014$) and WIT (PE: 4.84 ± 2.14; $p = 0.025$). Higher surgeon volume was associated with shorter WIT (PE: -0.06 ± 0.02; $p = 0.002$). Higher BMI was associated with longer OT (PE: 2.09 ± 0.56; $p < 0.001$); longer OT was associated with longer LOS (PE: 0.01 ± 0.01; $p = 0.002$). Finally, older age was associated with higher EBL (PE: 4.53 ± 2.08; $p = 0.030$) and nephrometry score was not associated with outcomes of interest.

Table 1 – Characteristics of the study sample

	Median (IQR)
Age, yr	60 (52–66)
Body mass index, kg/m^2, median	28.2 (25.6–32.6)
Maximum tumor diameter, cm	2.3 (1.7–3.1)
Preoperative serum creatinine, mg/dl	1.0 (0.6–1.3)
Preoperative GFR, ml/min	74.7 (49.46–99.94)
	n (%)
Male gender	142 (62.6)
Comorbidities	
Coronary artery disease	44 (19.4)
Hypertension	95 (41.9)
Diabetes mellitus	39 (17.2)
ASA score	
1	4 (1.8)
2	123 (54.2)
3	95 (41.9)
Missing	5 (2.2)
Prior abdominal surgery	29 (12.8)
Solitary kidney	1 (1.2)
Left kidney	119 (52.4)
Number of arteries	
1	173 (87.4)
2	45 (19.8)
3	6 (2.6)
Missing	3 (1.3)
Veins	
1	216 (95.2)
2	11 (4.8)
Radius	
≤4 cm	149 (65.6)
>4 but <7 cm	62 (27.3)
≥7cm	14 (6.2)
Missing	2 (0.9)
Exophytic	
Completely endophytic	33 (14.5)
<50% exophytic	78 (34.4)
≥50% exophytic	78 (34.4)
Missing	38 (16.7)
Nearness to collecting system	
≥7 mm	60 (26.4)
>4 but <7 mm	37 (16.3)
≤4 mm	91 (40.2)
Missing	39 (17.3)
Location	
Anterior	14 (6.3)
Posterior	159 (70.0)
Neither	28 (12.3)
Missing	26 (11.5)
Location relative to polar line	
Entirely peripheral to polar line	70 (30.8)
Cross the polar line	53 (23.4)
>50% of mass crosses polar line	47 (20.7)
Missing	57 (25.1)
Nephrometry score	
≤4	13 (5.7)
5–8	117 (52.0)
9–12	39 (17.2)
Missing	58 (25.6)

ASA = American Society of Anesthesiologists; GFR = glomerular filtration rate; IQR = interquartile range.

Table 2 – Perioperative and pathologic outcomes

	Median (IQR)
Operation time, min	165 (134–200)
Warm ischemia time, min	19 (16–24)
EBL, ml	75 (50–150)
Length of stay, d	2 (1–3)
Postoperative serum creatinine, mg/dl	1.01 (0.59–1.43)
Postoperative GFR, ml/min	76.0 (50–102)
	n (%)
Collecting system entry	
No	175 (77.1)
Yes	52 (22.9)
Selective clamping*	
Selective clamping	39 (17.2)
Nonselective clamping	181 (79.7)
Unclamped fashion	7 (3.1)
Conversions	
Radical nephrectomy	1 (0.44)
Transperitoneal robotic partial nephrectomy	2 (0.88)
Perioperative complication	
Clavien grade 1	
Urinary retention	4 (1.76)
Urine leak	1 (0.44)
Acute kidney injury	1 (0.44)
Redness	1 (0.44)
Pain	2 (0.88)
Numbness from right flank to groin	1 (0.4)
Fever	1 (0.4)
Pneumothorax	1 (0.4)
Clavien grade 2	
Atrial fibrillation	1 (0.4)
Myocardial infarction	1 (0.4)
Pneumonia	3 (1.3)
Blood transfusion	3 (1.3)
Clavien grade 3	
Urine leak	3 (1.3)
Pseudoaneurysm	3 (1.3)
Histology	
No cancer	45 (19.8)
Clear cell	143 (62.6)
Papillary type	21 (9.23)
Chromophobe	14 (6.2)
Cystic RCC	1 (0.4)
Unclassified	2 (0.9)
Positive margin	8 (3.5)
Pathologic stage	
T1a	99 (54.4)
T1b	55 (30.2)
T2a	16 (8.8)
T3a	12 (7.6)

EBL = estimated blood loss; GFR = glomerular filtration rate; IQR = interquartile range; RCC = renal cell carcinoma.

4. Discussion

According to guidelines, surgical excision, thermal ablation, and active surveillance are treatment options for appropriately selected clinical T1 renal masses [11]. However, the guidelines do not preempt physician judgment in individual cases, and treatment decisions vary depending on an urologist's training, biases, comfort levels, and individual experience [12]. The significance of tumor location on treatment choice is reinforced by the categorization of anterior and posterior location by both the RENAL nephrometry and PADUA scores [13,14]. For instance, although anterior or posterior tumor location did not affect the likelihood of open partial nephrectomy complications [14], it affects physician recommendation for thermal ablation and minimally invasive approaches to nephron-sparing surgery [4]. Thermal ablation and partial nephrectomy appear to have comparable outcomes, but thermal

ablation is associated with an eightfold greater use of surveillance imaging following treatment and greater frequency of computed tomography (CT) imaging. Radiation exposure increases the risk of secondary malignancies, and the costs of CT and magnetic resonance imaging contribute to the indirect health care costs of treating renal masses [15]. However, the use of thermal ablation to treat renal masses is increasing [16], and limited experience with the retroperitoneoscopy may contribute to referrals to radiologists for ablation of posteriorly and laterally located renal masses.

Our study has several important findings. First, we present a multicenter RARPN experience that is the largest to date and demonstrates significant variation in outcome by surgeon. Although all surgeons were fellowship trained in minimally invasive surgery, we demonstrate a significant heterogeneity in RARPN WITs and complications. For instance, after adjusting for nephrometry score and BMI and other observed differences in patient and tumor characteristics, one surgeon was significantly more likely to experience complications and had longer WITs by 4 min. This is significant given that longer WITs are associated with acute renal failure perioperatively and chronic kidney disease during long-term follow-up [17]. However, our WIT median of 19 min and IQR of 16–24 min is shorter than the 25-min cut-off established as a threshold for increased risk of acute renal failure and long-term stage IV chronic kidney disease [17].

Second, greater RARPN surgeon volume or experience was associated with shorter WITs. The surgeon volume–outcome relationship has been demonstrated for radical prostatectomy [18], radical cystectomy [19], and radical nephrectomy for RCC [20]. The learning curve for surgeons performing traditional laparoscopic partial nephrectomy has been estimated to be about 25 cases [21], with improved WIT noted with increasing surgical experience [22]. The transperitoneal robot-assisted partial nephrectomy learning curve for experienced robotic surgeons is similar at 20–30 cases required for acceptable outcomes [23]. However, these studies were single-surgeon series, and although we did not estimate a specific number for the RARPN learning curve due to our analysis of volume as a continuous variable, we demonstrate a clear association between RARPN surgeon volume and shorter WITs across multiple surgeons and institutions.

Third, our 3.5% likelihood of positive surgical margins is comparable with the published RARPN range of 0–5.6% [21,24–29], the 1.3–1.5% range for open partial nephrectomy [30,31], and the 2–7.1% range for laparoscopic retroperitoneal partial nephrectomy [32–34] (Table 3). In addition, our 0.9% recurrence rate is similar to the 1.5–6.0% range for these competing approaches to partial nephrectomy.

Fourth, higher BMI was associated with longer OTs. This finding parallels previous longer OTs among obese patients undergoing transperitoneal laparoscopic renal surgery [35] and transperitoneal robot-assisted partial nephrectomy [36]. However, obese versus nonobese patients have acceptable outcomes after retroperitoneal laparoscopic nephrectomy [37]. There may be an advantage to a retroperitoneal approach in the setting of high BMI because the retroperitoneal approach may bypass pannicular and intra-abdominal fat. For example, among extremely obese patients (BMI >40), retroperitoneal laparoscopic nephrectomy has less EBL and shorter OTs compared with the transperitoneal approach [38].Thus, although higher BMI was associated with longer OTs in our study, RARPN may have some advantages in this setting.

Finally, we demonstrate that the retroperitoneal approach is not associated with significant iatrogenic or overall complications, despite the intrinsically limited anatomic landmarks and greater familiarity with the

Table 3 – Surgical approach

Study	Sample size	Mean OT, min	Mean WIT, min	Mean EBL, ml	Mean LOS, d	Overall complications, %	Positive surgical margin, %	Cancer recurrence, %
Robot-assisted retroperitoneoscopic partial nephrectomy								
Hu et al.*	227	165	19	75	2	12.3	3.5	0.9
Open partial nephrectomy								
Gill et al. [30]	1029	258	20.1	376	5.8	13.7	1.3	1.5
Patard et al. [31]	600†	147	19.3	386	7.7	19.5	1.5	1.6†
Robot-assisted transperitoneal partial nephrectomy								
Ellison et al. [25]	108	215	24.9	368	2.7	33	5.6	0.9
Haber et al. [26]	75	200	18.2	323	4.2	16	1.3	NR
Jeong et al. [27]	31	170	20.9	198	5.2	NR	NR	6.4
Kural et al. [24]	11	185	26.5	286	3.9	9	0.0	0.0
Pierorazio et al. [21]	48	152	14.1	122	NR	10	4.2	NR
Seo et al. [28]	13	153	35.3	284	6.2	0	0.0	NR
Williams et al. [29]	27	233	18.5	180	2.5	22	0.4	NR
Laparoscopic retroperitoneal partial nephrectomy								
Marszalek et al. [32]	70	84	22.6	NR	5*	14	7.1	NR
Pyo et al. [33]	110	200	35	260	2.6	4.5‡	0.0	0.0
Ng et al. [34]	63	173	28.0	217	2.2	10	2.0	2

EBL = estimated blood loss; LOS = length of stay; NR = not reported; OT = operative time; WIT = warm ischemia time.
* Medians.
† For tumors ≤4 cm.
‡ Major complications.

transperitoneal approach. Our perioperative outcomes are comparable with alternative surgical approaches for nephron-sparing surgery (eg, open retroperitoneal, robot-assisted transperitoneal laparoscopic, and retroperitoneal laparoscopic approaches) (Table 3). The 1.3% likelihood of RARPN intraoperative complications—two transfusions due to high blood loss during renal mass excision and one self-resolving pneumothorax in our series—is comparable with the 2–10% reported for transperitoneal robot-assisted partial nephrectomy [39,40]. Together with our reported WIT, LOS, and EBL, our multisurgeon, multi-institutional RARPN study demonstrates that RARPN is safe and effective.

Our study must be interpreted in the context of the study findings. First, this is a retrospective study of prospectively collected surgeon data from fellowship-trained, high-volume surgeons at tertiary referral centers. As such, our results may not be applicable to the general urology population. Second, although we did not find an association between nephrometry score and outcomes, this may stem from the absence of tumors scored 11–12 and the fact that only 6% of tumors were >7 cm. Third, we have relatively limited follow-up to delineate long-term cancer control. Finally, subtle differences in RARPN technique may contribute to intersurgeon variation in outcomes; however, we describe center-specific differences in the RARPN approach and present a video to reinforce and highlight our approach.

5. Conclusions

RARPN is an effective approach to partial nephrectomy for posterior renal masses with acceptable oncologic outcomes and convalescence. Although there is significant variation in complications and WIT among experienced fellowship-trained surgeons, greater RARPN experience is associated with shorter WIT.

Author contributions: Jim C. Hu had full access to all the data in the study and takes responsibility for the integrity of the data and the accuracy of the data analysis.

Study concept and design: Hu, Weizer, Porter.
Acquisition of data: Xiong, McLaren, Stepanian.
Analysis and interpretation of data: Hu, Treat, Filson, McLaren, Xiong, Stepanian, Hafez, Porter, Weizer.
Drafting of the manuscript: Hu, Treat, Filson, McLaren, Xiong, Stepanian, Hafez, Porter, Weizer.
Critical revision of the manuscript for important intellectual content: Hu, Treat, Filson, McLaren, Xiong, Stepanian, Hafez, Porter, Weizer.
Statistical analysis: Hu, Xiong.
Obtaining funding: None.
Administrative, technical, or material support: Hu.
Supervision: Hu, Weizer, Porter.
Other (specify): None.

Financial disclosures: Jim C. Hu certifies that all conflicts of interest, including specific financial interests and relationships and affiliations relevant to the subject matter or materials discussed in the manuscript (eg, employment/affiliation, grants or funding, consultancies, honoraria, stock ownership or options, expert testimony, royalties, or patents filed, received, or pending), are the following: None.

Funding/Support and role of the sponsor: None.

Appendix A. Supplementary data

The Surgery in Motion video accompanying this article can be found in the online version at http://dx.doi.org/10.1016/j.eururo.2014.04.028 and via www.europeanurology.com.

References

[1] Lee CT, Katz J, Shi W, Thaler HT, Reuter VE, Russo P. Surgical management of renal tumors 4 cm. or less in a contemporary cohort. J Urol 2000;163:730–6.
[2] Hollingsworth JM, Miller DC, Daignault S, Hollenbeck BK. Rising incidence of small renal masses: a need to reassess treatment effect. J Natl Cancer Inst 2006;98:1331–4.
[3] Yu HY, Hevelone ND, Lipsitz SR, Kowalczyk KJ, Hu JC. Use, costs and comparative effectiveness of robotic assisted, laparoscopic and open urological surgery. J Urol 2012;187:1392–8.
[4] Finley DS, Beck S, Box G, et al. Percutaneous and laparoscopic cryoablation of small renal masses. J Urol 2008;180:492–8, discussion 498.
[5] Wright JL, Porter JR. Laparoscopic partial nephrectomy: comparison of transperitoneal and retroperitoneal approaches. J Urol 2005;174:841–5.
[6] Gaur DD, Agarwal DK, Purohit KC. Retroperitoneal laparoscopic nephrectomy: initial case report. J Urol 1993;149:103–5.
[7] McAllister M, Bhayani SB, Ong A, et al. Vena caval transection during retroperitoneoscopic nephrectomy: report of the complication and review of the literature. J Urol 2004;172:183–5.
[8] Weizer AZ, Palella GV, Montgomery JS, Miller DC, Hafez KS. Robot-assisted retroperitoneal partial nephrectomy: technique and perioperative results. J Endourol 2011;25:553–7.
[9] Patel M, Porter J. Robotic retroperitoneal partial nephrectomy. World J Urol 2013;31:1377–82.
[10] Benway BM, Wang AJ, Cabello JM, Bhayani SB. Robotic partial nephrectomy with sliding-clip renorrhaphy: technique and outcomes. Eur Urol 2009;55:592–9.
[11] Campbell SC, Novick AC, Belldegrun A, et al. Guideline for management of the clinical T1 renal mass. J Urol 2009;182:1271–9.
[12] Canter D, Kutikov A, Manley B, et al. Utility of the R.E.N.A.L. nephrometry scoring system in objectifying treatment decision-making of the enhancing renal mass. Urology 2011;78:1089–94.
[13] Kutikov A, Uzzo RG. The R.E.N.A.L. nephrometry score: a comprehensive standardized system for quantitating renal tumor size, location and depth. J Urol 2009;182:844–53.
[14] Ficarra V, Novara G, Secco S, et al. Preoperative aspects and dimensions used for an anatomical (PADUA) classification of renal tumours in patients who are candidates for nephron-sparing surgery. Eur Urol 2009;56:786–93.
[15] Kowalczyk KJ, Harbin AC, Choueiri TK, et al. Use of surveillance imaging following treatment of small renal masses. J Urol 2013;190:1680–5.
[16] Choueiri TK, Schutz FA, Hevelone ND, et al. Thermal ablation vs surgery for localized kidney cancer: a Surveillance, Epidemiology, and End Results (SEER) database analysis. Urology 2011;78:93–8.
[17] Thompson RH, Lane BR, Lohse CM, et al. Every minute counts when the renal hilum is clamped during partial nephrectomy. Eur Urol 2010;58:340–5.
[18] Hu JC, Gold KF, Pashos CL, Mehta SS, Litwin MS. Role of surgeon volume in radical prostatectomy outcomes. J Clin Oncol 2003;21:401–5.
[19] Konety BR, Dhawan V, Allareddy V, Joslyn SA. Impact of hospital and surgeon volume on in-hospital mortality from radical cystectomy:

data from the health care utilization project. J Urol 2005;173: 1695–700.
[20] Tan HJ, Wolf Jr JS, Ye Z, Wei JT, Miller DC. Complications and failure to rescue after laparoscopic versus open radical nephrectomy. J Urol 2011;186:1254–60.
[21] Pierorazio PM, Patel HD, Feng T, Yohannan J, Hyams ES, Allaf ME. Robotic-assisted versus traditional laparoscopic partial nephrectomy: comparison of outcomes and evaluation of learning curve. Urology 2011;78:813–9.
[22] Link RE, Bhayani SB, Allaf ME, et al. Exploring the learning curve, pathological outcomes and perioperative morbidity of laparoscopic partial nephrectomy performed for renal mass. J Urol 2005;173: 1690–4.
[23] Mottrie A, De Naeyer G, Schatteman P, Carpentier P, Sangalli M, Ficarra V. Impact of the learning curve on perioperative outcomes in patients who underwent robotic partial nephrectomy for parenchymal renal tumours. Eur Urol 2010;58:127–33.
[24] Kural AR, Atug F, Tufek I, Akpinar H. Robot-assisted partial nephrectomy versus laparoscopic partial nephrectomy: comparison of outcomes. J Endourol 2009;23:1491–7.
[25] Ellison JS, Montgomery JS, Wolf Jr JS, Hafez KS, Miller DC, Weizer AZ. A matched comparison of perioperative outcomes of a single laparoscopic surgeon versus a multisurgeon robot-assisted cohort for partial nephrectomy. J Urol 2012;188:45–50.
[26] Haber GP, White WM, Crouzet S, et al. Robotic versus laparoscopic partial nephrectomy: single-surgeon matched cohort study of 150 patients. Urology 2010;76:754–8.
[27] Jeong W, Park SY, Lorenzo EI, Oh CK, Han WK, Rha KH. Laparoscopic partial nephrectomy versus robot-assisted laparoscopic partial nephrectomy. J Endourol 2009;23:1457–60.
[28] Seo IY, Choi H, Boldbaatr Y, Lee JW, Rim JS. Operative outcomes of robotic partial nephrectomy: a comparison with conventional laparoscopic partial nephrectomy. Korean J Urol 2011;52:279–83.
[29] Williams SB, Kacker R, Alemozaffar M, Francisco IS, Mechaber J, Wagner AA. Robotic partial nephrectomy versus laparoscopic partial nephrectomy: a single laparoscopic trained surgeon's experience in the development of a robotic partial nephrectomy program. World J Urol 2013;31:793–8.
[30] Gill IS, Kavoussi LR, Lane BR, et al. Comparison of 1,800 laparoscopic and open partial nephrectomies for single renal tumors. J Urol 2007; 178:41–6.
[31] Patard J-J, Pantuck AJ, Crepel M, et al. Morbidity and clinical outcome of nephron-sparing surgery in relation to tumour size and indication. Eur Urol 2007;52:148–54.
[32] Marszalek M, Chromecki T, Al-Ali BM, et al. Laparoscopic partial nephrectomy: a matched-pair comparison of the transperitoneal versus the retroperitoneal approach. Urology 2011;77:109–13.
[33] Pyo P, Chen A, Grasso M. Retroperitoneal laparoscopic partial nephrectomy: surgical experience and outcomes. J Urol 2008; 180:1279–83.
[34] Ng CS, Gill IS, Ramani AP, et al. Transperitoneal versus retroperitoneal laparoscopic partial nephrectomy: patient selection and perioperative outcomes. J Urol 2005;174:846–9.
[35] Anast JW, Stoller ML, Meng MV, et al. Differences in complications and outcomes for obese patients undergoing laparoscopic radical, partial or simple nephrectomy. J Urol 2004;172:2287–91.
[36] Naeem N, Petros F, Sukumar S, et al. Robot-assisted partial nephrectomy in obese patients. J Endourol 2011;25:101–5.
[37] Doublet J, Belair G. Retroperitoneal laparoscopic nephrectomy is safe and effective in obese patients: a comparative study of 55 procedures. Urology 2000;56:63–6.
[38] Berglund RK, Gill IS, Babineau D, Desai M, Kaouk JH. A prospective comparison of transperitoneal and retroperitoneal laparoscopic nephrectomy in the extremely obese patient. BJU Int 2007;99: 871–4.
[39] Elsamra SE, Leone AR, Lasser MS, et al. Hand-assisted laparoscopic versus robot-assisted laparoscopic partial nephrectomy: comparison of short-term outcomes and cost. J Endourol 2013;27:182–8.
[40] Hughes-Hallett A, Patki P, Patel N, Barber NJ, Sullivan M, Thilagarajah R. Robot-assisted partial nephrectomy: a comparison of the transperitoneal and retroperitoneal approaches. J Endourol 2013; 27: 869–74.